

Evaluation of New Bone Formation and Osseointegration Around Subperiosteal Titanium Implants with Histometry and Nanoindentation

Noel Claffey, BDS, MDentSc¹/Haitham Bashara, DDS, MDentCh²/
Peter O'Reilly, MSc, MIEI³/Ioannis Polyzois, DMD, PhD⁴

Purpose: To assess the quality and quantity of newly formed bone around rough-surfaced titanium subperiosteal implants stabilized with two different fixation techniques and to investigate nanoindentation as a method for measuring the elastic properties of the bone around these implants. **Materials and Methods:** Ten 6-month-old white rabbits were used in this study. One femur received a subperiosteal implant fixed to the bone with screws. The other femur received a subperiosteal implant stabilized with a trough (bed) in the bone area, plus fixation screws. After a 3-month healing period, the animals were sacrificed and each titanium plate was resected along with the surrounding bone. Histometric measurements of osseointegration were performed on 16 titanium plates, and 16 titanium plates were evaluated qualitatively (hardness and modulus of elasticity) with nanoindentation. A regression model was used to analyze the data. **Results:** Subperiosteal implants placed into a trough performed significantly better than those placed on top of the cortical bone in terms of percentage of bone in direct contact with the titanium plate, length of new bone, and percentage of area of new bone. The mechanical properties (modulus of elasticity, hardness) of the newly formed bone above the plate measured at the microstructural level were significantly inferior to those of the mature cortical bone below the plate. **Conclusion:** Subperiosteal implants placed into a trough performed better than those placed on top of the cortical bone, but it seems that 3 months of healing is not enough to achieve optimal integration and bone maturation around them. Nanoindentation can offer valuable insight into the elastic properties of the microstructural component of the bone. *INT J ORAL MAXILLOFAC IMPLANTS* 2015;30:1004–1010. doi: 10.11607/jomi.3647

Key words: nanoindentation, subperiosteal, titanium implant

The subperiosteal implant was first described in the late 1940s, and different versions of this design evolved up to the late 1980s. They were primarily

fabricated from cobalt-chrome alloy, and professionals were initially satisfied with their performance. However, a clear drop in outcomes was seen after 5 and 10 years, and since the introduction of the highly successful endosseous implants in the 1960s the popularity of subperiosteal implants has declined dramatically.^{1–3} However, endosseous implants have some limitations; for example, a significant amount of augmentation is needed to use them in patients with highly resorbed jaws. Autogenous block grafts for this purpose are usually harvested from the hip or tibia of the patient and secured in different parts of the maxilla or mandible. This means that multiple procedures are required before endosseous implants can be placed.

Because of advances in biomaterials and imaging, subperiosteal implants could pose a good alternative and an attractive option for the treatment of atrophic jaws.^{4,5} The standard subperiosteal technique requires two surgical procedures: the first to replicate the bone anatomy with an impression, which has always been

¹Professor, Department of Restorative Dentistry and Periodontology, Dublin Dental School and Hospital, Trinity College Dublin, Ireland.

²Graduate Student, Department of Restorative Dentistry and Periodontology, Dublin Dental School and Hospital, Trinity College Dublin, Ireland.

³Senior Experimental Officer, School of Mechanical and Manufacturing Engineering, Trinity College Dublin, Ireland.

⁴Lecturer/Consultant, Department of Restorative Dentistry and Periodontology, Dublin Dental School and Hospital, Trinity College Dublin, Ireland.

Correspondence to: Dr Ioannis Polyzois, Department of Restorative Dentistry and Periodontology, Dublin Dental School and Hospital, Trinity College Dublin, Dublin 2, Ireland. Fax: +353-11-6127297. Email: ioannis.Polyzois@dental.tcd.ie

©2015 by Quintessence Publishing Co Inc.

considered very technique sensitive; and the second to place the implant. With the advancement of three-dimensional computed tomographic technology and stereolithography, the first surgery is no longer necessary.⁶

In addition to the aforementioned advancements in imaging and three-dimensional reproduction of bone anatomy, increased degrees of osseointegration and structural strength have been achieved with new titanium alloys and enhanced implant surfaces. Because the amount of bone that covers subperiosteal implants is substantially smaller than the amount of bone covering a typical endosseous implant, the quality of this bone is of paramount importance.

Although histomorphometric analysis has been the gold standard means to measure the quantity of osseointegration, nanoindentation was recently introduced as a reliable way of measuring the biomechanical properties of bone tissue around implants.⁷⁻⁹ In nanoindentation, a machine is used to place nano-sized indents on the surface of a material. This is similar in principle to a basic hardness testing machine. As such, an indenter is allowed to impinge upon the surface of a specimen under the action of a controlled load. The main advantage in using this machine is that it can obtain accurate hardness values as well as elastic modulus (stiffness) values for the material tested. Additionally, because the method operates on the nano scale, it can measure differences in the hardness and elastic modulus of different phases contained within one specimen of the material, each of which may be only a few microns in size.¹⁰

It was the authors' goal to investigate the possibility of superficial titanium osseointegration and assess the quality and quantity of newly formed bone around rough-surfaced titanium subperiosteal implants 3 months after their placement onto the cortical bone of rabbit tibiae.

MATERIALS AND METHODS

The protocol for this study was in accordance with the animal research policies of the Department of Health and Children in Ireland. Ten 6-month-old female white rabbits weighing about 2 kg each were used in this study and were housed in groups of two in the animal house of the Bio-resources Unit at Trinity College Dublin. All rabbits were given free access to food (laboratory chow) and water at all times. The animal holding facility was on a 12-hour light/dark cycle and the room temperature was kept between 20°C and 23°C.

Each animal received treatment in both femora. One femur received a subperiosteal implant (fixation plate) that was anchored to the bone with fixation

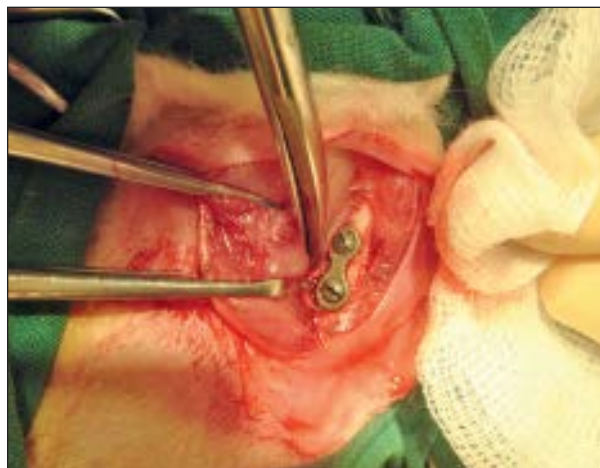

Fig 1 Subperiosteal dissection of a rabbit femur, followed by placement of an implant.

screws (2 × 4 mm) (Libinger/Stryker). The other femur received an identical subperiosteal implant that was anchored with a trough (bed) in the bone area, along with the same fixation screws. This trough was created "free hand" but always with the same size bur to ensure all troughs were of similar size. The width of each implant was 2.5 mm and the height was 1 mm (Fig 1). The implants were sandblasted to increase their roughness. Ethical approval and a license to perform the study were obtained.

Surgical Procedure

Anesthesia was achieved with an intramuscular injection of a 1:1 mixture of xylazine hydrochloride (2%) and ketamine at a dose of 0.15 mL/100 g (Sigma-Aldrich). The skin of the hind legs was shaved and sprayed liberally with 70% alcohol. The medial part of each femur was exposed via a skin incision and careful subperiosteal dissection. Perforations in the underlying cortex were made with a 1-mm bur, and the implant was fixed with two 4-mm fixation screws. The periosteum and muscular layers were repositioned and sutured. The skin flaps on both sides were then closed with 3-0 black silk (Ethicon, Johnson & Johnson) interrupted sutures to achieve complete wound closure. A similar procedure was performed in the contralateral femur, but a trough was made and used as a rest for the titanium implant before the two fixation screws were inserted. The bed was 0.5 mm deep and prepared with a 1-mm round bur. Immediately after surgery, a single intramuscular injection of oxytetracycline (50 mg/kg, Aldrich Chemical Company) was administered to each rabbit.

Each rabbit was monitored postoperatively, and antibiotics (gentamicin, 0.05 mL/kg, Hospira) were

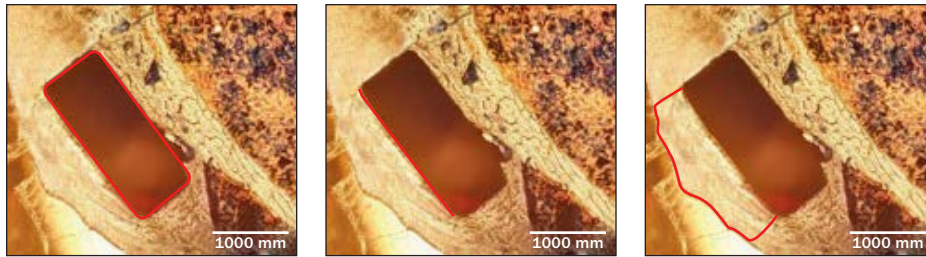


Fig 2 (left) Linear measurement of percentage of bone in direct contact with titanium plate.

Fig 3 (center) Linear measurement of percentage of bone covering the titanium plate.

Fig 4 (right) Percentage of area of new bone formed in contact with the titanium plate.

administered intramuscularly once daily for 5 days. Analgesia was administered postoperatively and subsequently as necessary. For the duration of the recovery period, animals were housed in the Bio-resources Unit under veterinary supervision. Two animals died during the healing period.

Preparation of Specimens

After 3 months of healing, the eight remaining animals were sacrificed by intravenous injection of 200 mg/kg of phenobarbitone (Rhône Mérieux). Each titanium plate was resected along with the surrounding bone from each tibia using a disk (Superlex, Edenta) mounted in a straight handpiece at 100 rounds per second using water as coolant.

All dehydration and embedding procedures of the specimens were performed in accordance with the protocol used at the Royal College of Surgeons in Ireland and were described in detail by O'Brien and O'Reilly.^{11,12} A block of bone containing the mini-implant and about 5 mm of surrounding bone was obtained for each experimental site. The soft tissue surrounding the femur was completely removed using a scalpel with a no. 15 blade (Swann-Morton). The bone specimens were then dehydrated. Each specimen was first completely immersed in a vial containing 80% ethanol for 4 days. The 80% ethanol solution was then changed to 95% and 100% ethanol solutions, respectively, for 1 day each. A fresh solution of 100% ethanol was applied for 1 more day. Finally, the specimens were immersed in acetone for 2 days.

All femurs were separately embedded in a methylmethacrylate polymer (MMA) (Sigma-Aldrich). The MMA polymer consisted of a monomer (pure MMA, 200 mL), a softener (dibutyl phthalate, 50 mL), and a catalyst (benzoyl peroxide, 7 g). The softener was added to the monomer to avoid brittleness of the finished polymer, while the catalyst caused the solution to polymerize when the temperature was increased. Each femur block was placed in a separate vial and infiltrated with the MMA solution at room temperature under vacuum desiccation (50 mm Hg) over a period of 3 days. The polymer was changed with fresh MMA

solution daily. Specimens were then placed into an oven at 55°C for 4 days to complete polymerization.¹¹

To obtain three sections of 150 to 200 μ m thickness from the middle of each experimental site, the embedded blocks were mounted on a diamond saw (Minitom, Struers). A cut was made vertically through the center of each implant and the block was sectioned. One piece was used for nanoindentation; from the other, three sections (300 μ m thickness) were obtained for histomorphometric analyses.

Each section was placed over a sheet of no. 400 silicon carbide paper (wet and dry, waterproof abrasive paper, D. O'Sullivan & Company Ltd). Another piece of carbide paper was wrapped around the glass slide, and the section was manually ground down under running water. The thickness was checked regularly using a micrometer screw until a thickness of 150 to 200 μ m was obtained. Specimens were washed with tap water, placed in a test tube, and washed with distilled water. Specimens were then dried using paper and mounted on glass slides using mounting medium DPX (Eukitt's mounting medium) under a glass cover slip.

Histometry

The slides were magnified under a light microscope by $\times 12.5$, and the images were captured with an Optronic charge-coupled distributor digital microscope camera. Analysis software (Scion Image Beta 4.02 Win, Scion PCI Frame Grabber boards) was calibrated to present all measurements in millimeters.

Histometric analysis was carried out for each site of the titanium plates as follows. Sixteen titanium plates were evaluated, and quantification of bone contact with the titanium plate was measured for both the original bone and the newly formed bone by means of three measurements on each section: (1) linear measurement of percentage for the periphery of titanium plate in direct contact with bone (Fig 2); (2) linear measurement of bone in contact with the superficial aspect of the titanium plate (Fig 3); and (3) calculated area (in square millimeters) of new bone formed superficial to the titanium plate (Fig 4).

Analysis of variance (ANOVA) was used to assess the differences between group means. Depending on the direction of each section, minor differences were observed in the length and height of each implant. This was taken into consideration and included in the statistical analyses to correct for any possible effect that these differences might have on the results (regression analysis).

Nanoindentation

Before each block was placed into the nanoindenter, its surface was polished with silicon polishing paper (800 grit) and two diamond polishing disks (Fig 5). The final smoothness was 1 μm . Each embedded block had to stay in the nanoindenter for 17 hours.

A load of 50 mN was applied three times consecutively at each indent location using a Berkowitz indenter (MTS Nanoindenter XP). Elastic modulus and hardness values were obtained from the last unloading curve on each sample. The load was applied three times to remove any viscoelasticity effect. It was observed that the hysteresis was lessening with each indent. This load of 50 mN produced a depth of approximately 1,800 nm or 1.8 μm .

Nanoindentation is a novel way of looking at the process of osseointegration and testing the mechanical characteristics of newly formed bone. These properties were tested in three areas and 12 sites: area 1 (four "internal" bone sites), area 2 (four "peripheral" bone sites), and area 3 (four "new bone" sites) (Fig 6).

ANOVA was used to assess the differences between group means, and a regression model was used to measure the effects of any factors, such as area and animal, on these differences.

RESULTS

Direct Contact of Bone with Periphery of Plate

The values for the percentage of bone in direct contact with the titanium plate surface are displayed in Table 1. For sites with no trough, the values ranged from 70.5% to 83.1%, and the mean was 76.5% (standard deviation [SD], 3.79%). For sites with a trough, the values ranged from 78.5% to 89.9% and the mean (SD) was 86.5% (3.46%). There were significant differences between the group means (ANOVA; F ratio = 14.1536, $P < .0005$).

The results of the effect tests are displayed in Table 1. A significant difference ($P = .0002$) was found for modality (trough vs no trough) after controlling for the histologic length of the titanium plate.

Direct Contact of Bone and Superficial Aspect of Plate

The values for bone in direct contact with the superficial aspect of the titanium plate surface are displayed in Table 1. For sites without a trough, the values ranged from 1.41 to 1.53 mm, and the mean (SD) was 1.50 mm (0.006 mm). For sites with a trough, the values ranged from 1.71 to 1.86 mm and the mean (SD) was 1.78 mm (0.002 mm). There were significant differences between group means (ANOVA; F ratio = 40.8492, $P < .0001$).

The result of the effect tests are displayed in Table 1. A significant difference ($P = .0001$) was found for modality (trough vs no trough) after controlling for the histologic length of the titanium plate.

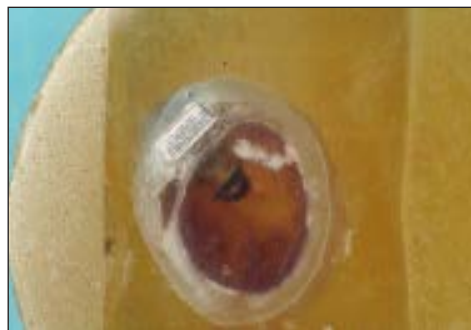

Fig 5 Embedded block.

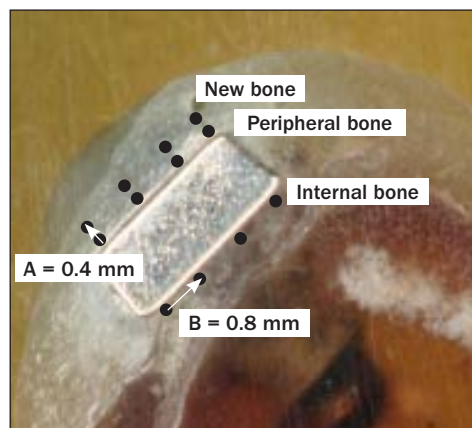


Fig 6 Measurement sites for osseointegration in newly formed bone. The measurements were made at eight points, each 0.8 mm apart, along the length of the plate (peripheral and internal) as well as at four points, 0.8 mm apart and 0.4 mm into the newly formed bone (new bone) on the external surface of the plate (distance A = 0.4 mm; distance B = 0.8 mm; thickness of the plate = 1 mm; length of the plate = 2.5 mm).

Projected Area of New Bone Superficial to the Plate

The values for bone in direct contact with the superficial aspect of the titanium plate surface are displayed in Table 1. For sites without a trough, the values ranged from 1.27 to 1.4 mm², and the mean (SD) was 1.30 mm² (0.006 mm²). For sites with a trough the values ranged from 1.88 to 1.95 mm², and the mean (SD) was 1.78 mm² (0.002 mm²). There were significant differences between group means (ANOVA; F ratio = 1160.071, $P < .0001$).

The results of the effects test are displayed in Table 1. A significant difference ($P = .0001$) was found for modality (trough vs no trough) after controlling for the histologic length of the titanium plate.

Table 1 Histometric Values for 16 Examined Specimens

Modality/ specimen no.	Plate length (mm)	BIC (%)*	Length of new bone (mm) [†]	Area (mm ²) [‡]
1 (no trough)				
1	6.9	80.5	1.53	1.28
2	6.1	70.5	1.48	1.32
3	6.02	83.1	1.68	1.29
4	6.88	75	1.41	1.34
5	6.96	75.5	1.48	1.27
6	6.01	76.6	1.56	1.31
7	6	76	1.52	1.32
8	6.98	75.2	1.49	1.28
2 (trough)				
1	6.02	88.5	1.8	1.91
2	6	78.5	1.78	1.89
3	6.96	89.4	1.71	1.93
4	6.08	86.4	1.86	1.88
5	6.99	86.8	1.72	1.94
6	6.98	85.7	1.8	1.92
7	6.1	88.5	1.85	1.9
8	6.09	88.2	1.78	1.95

*ANOVA: F ratio = 14.15, P = .0005; effect test: F ratio = 25.75, P = .0002.
[†]ANOVA: F ratio = 40.84, P < .0001; effect tests: F ratio = 55.54, P < .0001.
[‡]ANOVA: F ratio = 1,160.071, P < .0001; effects test: F ratio = 1,999.68, P < .0001.

Table 2 Mean Values for Hardness and Modulus of Elasticity for the Three Areas for All 16 Embedded Blocks

	New bone (area 1)	Peripheral bone (area 2)	Internal bone (area 3)
Modulus of elasticity	33.2 GPa	32.5 GPa	38.9 GPa
Hardness	0.44 GPa	0.63 GPa	0.80 GPa

Table 3 Mean Values (GPa) of Hardness and Modulus of Elasticity for All Eight Animals

	1	2	3	4	5	6	7	8
Modulus of elasticity	27.2	36.1	36.2	38.5	34.7	27.0	32.5	42.5
Hardness	0.6	0.8	0.7	0.7	0.6	0.5	0.6	0.6

Table 4 Effects Test for Modulus of Elasticity

	DF	F ratio	Probability
Area	2	25.9	< .0001
Animal	8	18.9	< .0001
Area/animal	16	4.7	< .0001

Table 5 Effects Test for Hardness

	DF	F ratio	Probability
Area	2	107.9	< .0001
Animal	8	9.2	< .0001
Area/animal	16	5.9	< .0001

The results show that there were significant differences in the amount of osseointegration, as well as the amount of bone covering the titanium implants between the two treatment modalities. It seems that the subperiosteal implants placed into a trough performed better than those placed on top of the cortical bone. Differences in the histologic plate length caused by differing orientations of sections were factored into the statistical analyses and were found not to influence the results.

Mean Values for Hardness and Elasticity Modulus

The mean values for hardness and modulus of elasticity for the three areas tested are displayed in Tables 2 and 3, respectively. ANOVA showed that there were significant differences between the mean values of the three areas and for both hardness (F ratio = 14.86, P < .0001) and modulus of elasticity (F ratio = 10.83, P < .0001).

In the effects test for both measurements, the bone internal to the plate showed an appreciably higher value. Both effects studies (area and animals) were significantly different for both area and animals (Tables 4 and 5).

It was demonstrated that, although integration of the miniplates to the rabbit femur bone was achieved and a significant amount of bone was formed over the plates over a 3-month period, the mechanical properties of the newly formed bone measured at the microstructural level were inferior to those of the mature cortical bone below the plate.

DISCUSSION

It was the authors' intent to investigate the possibility of superficial titanium osseointegration and assess the quantity and quality of newly formed bone around rough-surfaced titanium subperiosteal implants that could be used in the future as part of a subperiosteal mesh. A multimodality experimental approach was used in the study herein that combined nanoindentation measurements with histologic examination. The measurements were made continuous to the titanium plate as well as into the newly formed bone on the external surface of the plate 12 weeks after insertion of the plate.

When subperiosteal implants are placed, it is expected that only a small amount of bone will be covering them compared to standard endosseous implants. This was confirmed histologically in this study, where only a thin layer of cortical bone covered the implants. More bone was observed over the implants that had been placed in a trough. To compensate for this lack of bone volume, a human study in 1972 and a number of studies performed a few years later showed encouraging results when bone grafting was performed simultaneously with the placement of subperiosteal implants.^{13–15} However, the long-term results did not show significant differences between grafted and ungrafted sites. A recent case report demonstrated that severe mandibular atrophy was treated with a specially designed hydroxyapatite (HA)-coated subperiosteal implant that allowed for simultaneous grafting with recombinant human bone morphogenetic protein-2 and mineralized allograft. After 32 months of healing, cone beam computed tomographic images showed bone regeneration underneath the implant. However, the available literature is limited and, in some cases, controversial.¹⁶ The linear measurement of the percentage of bone in direct contact (BIC) with the titanium plate calculated on the histologic slides ranged between 70.5% and 89.5% and is similar to what has been presented in the international literature for root-form rough-surfaced implants.^{17,18}

The lack of the necessary quantity of bone necessary to provide the subperiosteal implants with stability renders the mechanical properties (quality) of bone surrounding these implants more important. It seems that 3 months of healing is not sufficient to achieve optimal integration and bone maturation around these implants. Because there is not enough evidence to support that nanoindentation techniques accurately measure time-dependent properties of bone, a potential direction for future research would be to measure the maturation of cortical bone around a similar subperiosteal implant over time and in the long term.¹⁹ In this way it may be possible to identify the most appropriate time for loading as well as the long-term effects of this loading.

Both modulus of elasticity and hardness were greater within established bone than within newly formed bone. It is not known whether this result would differ over a longer time period.

A recent study investigated the evolution of the hardness and indentation modulus of newly formed bone tissue as a function of healing time.⁷ The authors used a sample of three titanium disks, which were placed in three rabbits, and they performed both histologic and nanoindentation tests at 4, 7, and 13 weeks. The results of this study demonstrated that the biomechanical properties of newly formed bone were

different from those of mature bone tissue, which is in agreement with the current study.

In another recent animal study, 10 threaded implants were placed in 10 rabbits to examine the effect of a nanoscale HA-coated implant surface on osseointegration after 3 weeks of healing. These implants were compared to 10 other implants (grit-blasted, acid-etched, and heat-treated). While both implants showed similar BIC, the nanoindentation was sufficiently sensitive to demonstrate that the tissue quality was significantly enhanced around the HA-coated implants.⁸

Baldassarri et al evaluated the long-term changes in elastic modulus and hardness of cortical bone around retrieved root-formed implants. Thirty implants were retrieved after 0.3 to 24 years of functional loading. Both hardness and elastic modulus presented increased values with time after implant placement, but beyond 5 years after placement, these values stabilized.⁹

The study adds to the existing body of evidence and demonstrates that the nanoindentation method can offer valuable insight into the elastic properties of the microstructural component of bone and improve the understanding of the complex biologic mechanisms that take place around subperiosteal implants.

CONCLUSIONS

In this study there was a significant difference between the amount of osseointegration as well as the amount of bone covering the titanium implants between the two treatment modalities. On average, the subperiosteal implants placed into a trough performed better than those placed on top of the cortical bone. It was also demonstrated that at 3 months, the mechanical properties of the newly formed bone measured at the microstructural level were inferior to those of the mature cortical bone below the plate.

ACKNOWLEDGMENTS

The authors reported no conflicts of interest related to this study.

REFERENCES

1. James RA, Lozada JL, Truitt PH, Foust BE, Jovanovic SA. Subperiosteal implants. *CDA J* 1988;16:10–14.
2. Bodine R, Yanase R. 30-year report on 28 implant dentures inserted between 1952 and 1959. International Symposium on Preprosthetic Surgery, Palm Springs, CA, 1985.
3. Zwirger S, Abu-Id MH, Kreusch T. Long-term results of fitting subperiosteal implants: Report of twelve patient cases. *Mund Kiefer Gesichtschir* 2007;11:359–362.
4. McAllister M. Application of stereolithography to subperiosteal implant manufacture. *J Oral Implantol* 1998;24:89–92.

5. Kusek E. The use of laser technology (Er:Cr:YSGG) and stereolithography to aid in the placement of a subperiosteal implant: Case study. *J Oral Implantol* 2009;35:5–11.
6. Stoler A. Helical CT scanning for CAD/CAM subperiosteal implant construction. *J Oral Implantol* 1996;22:247–257.
7. Vayron R, Barthel E, Mathieu V, Anagnostou ESF, Haiat G. Nanoindentation measurements of biomechanical properties in mature and newly formed bone tissue surrounding an implant. *J Biomech Eng* 2012;134:260–266.
8. Jimbo R, Coelho PG, Bryington M, et al. Nano hydroxyapatite-coated implants improve bone nanomechanical properties. *J Dent Res* 2012;91:1172–1177.
9. Baldassarri M, Bonfante E, Suzuki M, et al. Mechanical properties of human bone surrounding plateau root form implants retrieved after 0.3-24 years of function. *J Biomed Mater Res Appl Biomater* 2012;100B:2015–2021.
10. Oliver W, Pharr G. An improved technique for determining hardness and elastic modulus using load and displacement sensing indentation experiments. *J Mater Res* 1992;7:1564–1583.
11. O'Brien FJ. *Microcracks and Fatigue Behaviour of Compact Bone* [thesis]. Dublin, Ireland: University of Dublin, 2000.
12. O'Reilly P. *Torsional Fatigue of Cortical Bone* [thesis]. Dublin, Ireland: University of Dublin, 2002.
13. Kratochvil FJ, Boyne P. Combined use of subperiosteal implant and bone-marrow graft in deficient edentulous mandible: A preliminary report. *J Prosthet Dent* 1972;27:645–653.
14. Kratochvil FJ, Boyne P, Bump RL. Rehabilitation of grossly deficient mandibles with combined subperiosteal implants and bone graft. *J Prosthet Dent* 1976;35:452–461.
15. Golec TS, Cutri AA. Treatment of the acutely atrophic mandible with a combined subperiosteal implant and bone graft. *J Oral Implantol* 1982;10:371–378.
16. Loperfido C, Mesquida J, Lozada JLL. Severe mandibular atrophy treated with a subperiosteal implant and simultaneous graft with rhBMP-2 and mineralized allograft: A case report. *J Oral Implantol* 2014;40:707–713.
17. Bornstein MM, Valderrama P, Jones AA, Wilson TG, Seibl R, Cochran DL. Bone apposition around two different sandblasted and acid-etched titanium implant surfaces: A histomorphometric study in canine mandibles. *Clin Oral Implants Res* 2008;19:233–241.
18. Buser D, Broggini M, Wieland RK, et al. Enhanced bone apposition to a chemically modified SLA titanium surface. *J Dent Res* 2004;83:529–533.
19. Isaksson H, Malkiewicz M, Nowak R, Helminen HJ, Jurvelin JS. Rabbit cortical bone tissue increases its elastic stiffness but becomes less viscoelastic with age. *Bone* 2010;47:1030–1038.