

Severe Mandibular Atrophy Treated With a Subperiosteal Implant and Simultaneous Graft With rhBMP-2 and Mineralized Allograft: A Case Report

Cosimo Loperfido, DDS, MSc^{1*}

Juan Mesquida, DDS²

Jaime L. Lozada, DMD²

A 71-year-old patient was successfully rehabilitated by means of a 3D model-derived, hydroxyapatite-coated titanium subperiosteal mandibular implant. The implant was specifically designed to allow bone augmentation. The deficient bone was simultaneously grafted with mineralized bone allograft and recombinant bone morphogenetic protein –2 (rhBMP–2). The 32-month postoperative cone beam computerized tomography follow-up showed vertical bone augmentation beneath the implant frame.

Key Words: *subperiosteal implant, allograft, BMP, vertical augmentation*

INTRODUCTION

Resorption of the alveolar ridge represents a challenge for dental implant placement. Through the years, different techniques have been used to allow dental implant placement in sites with deficient alveolar bone volume. In previous decades, subperiosteal implants were extensively utilized in patients with severe bone resorption.^{1,2,3} The subperiosteal implant was first described in the mid-1940s,⁴ then further refined by Goldberg⁵ and Linkow;¹ throughout the years it has undergone significant changes and improvements in terms of materials and shape.

One of the major problems attributed to the use of the early subperiosteal implants was the fibrous encapsulation that led to implant movement during occlusal load and eventually to bone loss and implant failure.⁶ Starting with the early 1970s, the researchers' attention focused on how to prevent bone resorption, improve bone volume, and allow

the integration of the implant with the surrounding bone.

In 1972, a preliminary human study demonstrated the feasibility of autogenous bone graft performed simultaneously with a subperiosteal implant.⁷ A few years later, the same authors showed in a *Macaca mulatta* monkey study that grafting the atrophic mandible with autogenous bone and hydroxyapatite, while simultaneously placing a subperiosteal implant, led to stable bone formation underneath the implant at the 6-month follow-up.⁸ During the same time period, similar studies showed encouraging results.⁹ The rationale of using a bone graft underneath a subperiosteal implant was based on the possibility of obtaining a more resorption-resistant alveolar ridge,² allowing osseointegration of the implant,² and protecting the alveolar nerve which, in these cases, is usually dehiscent.⁷ However, in the early 1980s, the utility of bone grafts performed alongside subperiosteal implants remained questionable, since long-term results had not shown substantial differences between grafted and nongrafted mandibles after implant placement.⁶

In recent years, interest in bone morphogenetic proteins (BMPs) has grown considerably. Bone

¹ Private practice, London, United Kingdom.

² Loma Linda University School of Dentistry, Loma Linda, Calif.

* Corresponding author, e-mail: cosimo.loperfido@gmail.com

DOI: 10.1563/AAID-JOI-D-12-00132

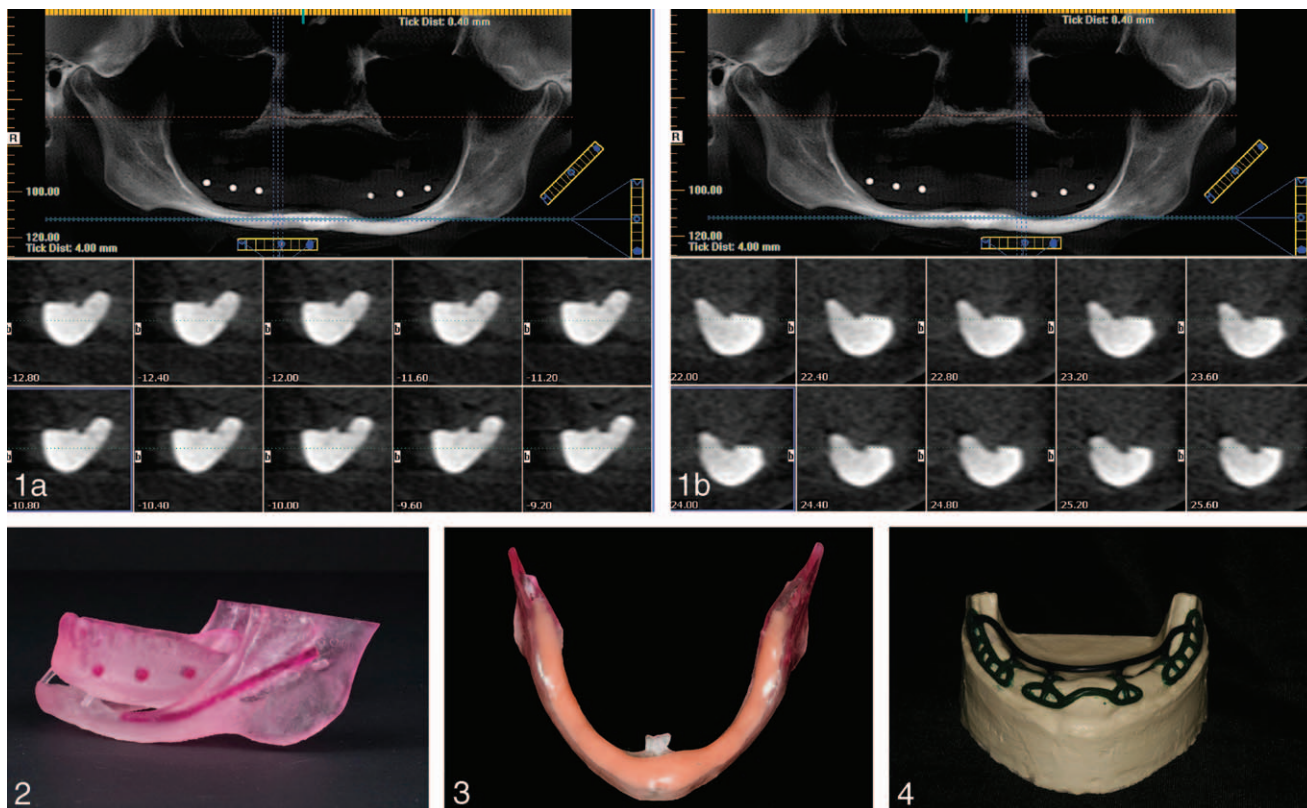


FIGURE 1. (a) pre-operative CBCT right mandible. (b) pre-operative CBCT left mandible. **FIGURE 2.** Stereolithographic model of the patient's mandible and complete denture. **FIGURE 3.** Build-up of the mandibular anatomy to the desired alveolar dimension. **FIGURE 4.** Refractory stone model with the subperiosteal implant created in wax.

morphogenetic proteins are multifunctional proteins with a wide range of biologic activities, involving a variety of cell types. Bone morphogenetic proteins belong to the super-family of transforming growth factor- β .¹⁰ BMPs bind specific receptors to a variety of different cell types, including mesenchymal stem cells, osteoblasts, and osteoclasts. Subsequently, these receptors activate second-messenger systems within the cellular cytoplasm, which, in turn, leads to intramembranous bone formation when a high concentration of BMPs is present.¹¹ Although more than 20 BMPs have been discovered, only BMP -2, -4, -6, -7 and -9 have proved to be capable of driving multipotent cells into an osteoblastic phenotype culture.^{12,13}

The aim of this paper is to present a case in which a severely atrophic mandible was successfully treated with a 3D model-derived titanium-hydroxyapatite (HA)-coated subperiosteal implant and simultaneous grafting with rhBMP-2/mineralized allograft.

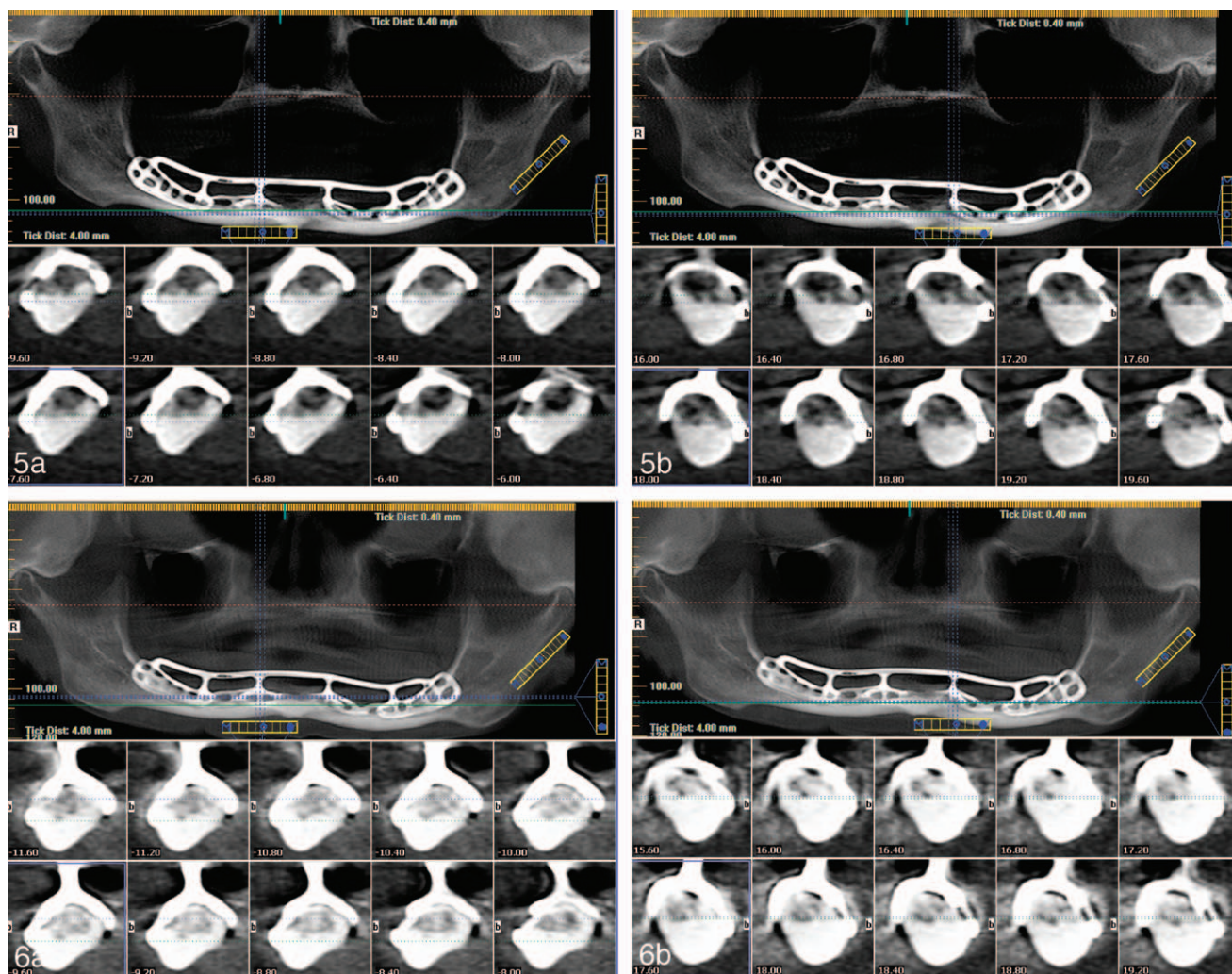
CASE REPORT

A 71-year-old healthy female patient presented for implant treatment for her mandibular edentulism at the Center for Implant Dentistry, Loma Linda University, California, USA.

The preoperative cone-beam computerized tomography (CBCT) showed severe bone resorption that included not only all of the alveolar bone, but also part of the basal bone (Figure 1a and b).

Because of severe bone resorption and the patient's own wish to avoid extensive bone grafting, the placement of a subperiosteal implant was planned.

The subperiosteal implant was fabricated by utilizing a modification of the technique described previously by Truitt.¹⁴ Briefly, a stereolithographic model (Figure 2) was fabricated based on the digital imaging and communication in medicine (DICOM) information acquired by a CBCT acquisition (I-cat Classic, Imaging Sciences International, Hatfield, Penn). The stereolithographic model reproducing patient mandibular anatomy was built up to the



FIGURES 5 AND 6. **FIGURE 5.** (a) Immediate postoperative CBCT follow-up right mandible. (b) Immediate postoperative CBCT follow-up left mandible. **FIGURE 6.** (a) 32-month CBCT follow-up right mandible. (b) 32-month CBCT follow-up left mandible.

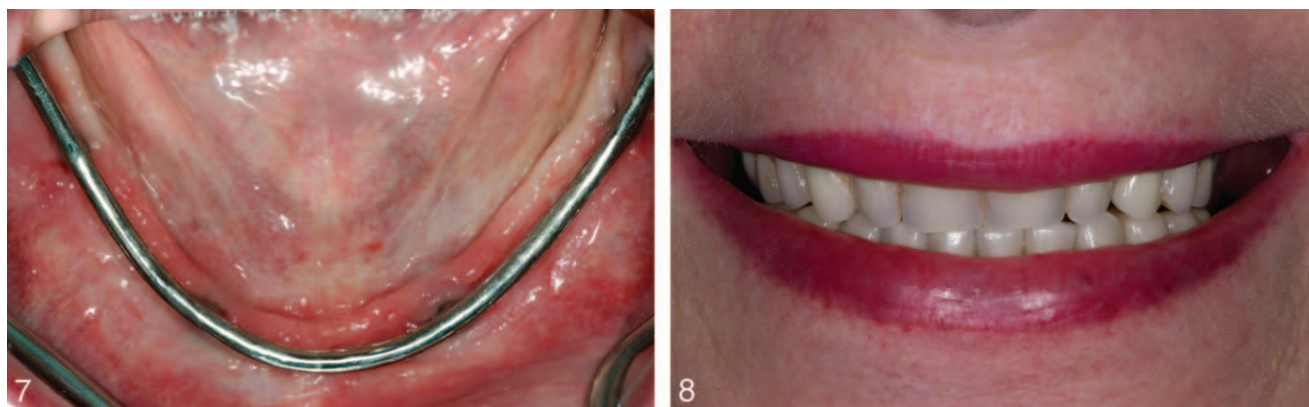desired alveolar dimensions, utilizing a moldable artificial gingival material (GI-Mask, Coltène Whaledent, Switzerland; Figure 3). After the ideal contour was achieved, an impression was taken of the stereolithographic model and a refractory stone model was created. Subsequently, the design of the future subperiosteal implant was created in wax (Figure 4) and then cast in titanium alloy and coated with HA particles.

The surgical treatment was performed under local anesthesia. After a crestal incision from retromolar to retromolar area, the flap was elevated and the titanium type-IV hydroxyapatite-coated subperiosteal implant (Implantlab, San Diego, Calif) was inserted.

After implant insertion, the absorbable collagen sponge (ACS) carrier was cut in small pieces and

soaked with rhBMP-2 (Infuse bone graft, Medtronic, Minneapolis, Minn). Subsequently, the pieces were mixed together with mineralized bone allograft (Puros allograft, Zimmer Dental, Carlsbad, Calif) and the resulting mixture was used to graft the subperiosteal implant. Primary closure was achieved with GORE-TEX sutures.

Healing was uneventful and sutures were removed after 15 days. The implant was loaded 3 months later. CBCT was taken immediately after surgery (Figures 5a and b) and at 32 months after implant insertion (Figures 6a and b). The 32-month CBCT follow-up showed maturation of the bone graft and vertical bone gain (Figures 6a and b). At the 32-month follow-up, the implant in fully functional occlusion was clinically stable (Figures 7 and 8).



FIGURES 7 AND 8. **FIGURE 7.** 32-month follow-up patient's occlusal view. **FIGURE 8.** 32-month follow-up patient's smile.

DISCUSSION

This report is the first documented case in which rhBMP2 (Medtronic) and mineralized allograft (Zimmer Dental) were used with the intent to promote bone regeneration underneath a subperiosteal implant and osseointegration of the implant itself. The shape of our implant followed the guidelines proposed by James.^{15,16} The implant rested mainly on areas that tend to resist the resorption of the alveolar ridge: the genial tubercle and the two retromolars. This even distribution of forces may result in good alveolar bone maintenance. Furthermore, the implant design allowed grafting in those areas that are usually deficient of bone, like the parasymphiseal and molar/premolar area. The implant was HA coated, in order to promote possible osseointegration. The available literature on subperiosteal implants placed simultaneously alongside bone grafts is limited and controversial. While different authors agreed on the usefulness of the bone graft,^{2,7-9} in the only long-term study available on the subject, the author concluded that there were no significant clinical results, in terms of failure rate and complications, when comparing chromium-cobaltum subperiosteal implants placed with or without autogenous bone graft harvested from the ilium.⁶ The same article also pointed out that some bone gain was evident at 1-year postoperative panoramic X rays, but still the implant success rate was around 68% at the 5-year follow-up. A more recent retrospective study¹⁷ showed that HA-coated subperiosteal implants placed over a 10-year period had a 91% success rate. However, during those 10 years, 36% of implants needed additional corrective interventions.

In the same study, the subperiosteal implants constructed using a 3D model showed a 100% success rate up to the 9-year follow-up. In our case, we also used a 3D model-derived, HA-coated titanium implant. The 32-month CBCT follow-up showed extensive bone formation. Bone growth phenomenon in severely resorbed mandibles has been previously documented in a large number of cases in which transmandibular implant systems were used.¹⁸⁻²⁰ However, those studies were based on panoramic images and no standardization technique was implemented in order to prevent possible measurement errors.^{21,22} Bone growth was also reported for ramus frame implants.²³ A case of bone growth after using a subperiosteal implant was reported by Fish.²⁴ In this case, a tripod HA-coated subperiosteal implant placed in 1985 showed bone growth above the mandibular canal in a panoramic X ray taken 14 years later. Bone growth was confirmed also at clinical re-entry. All previous reports of bone growth in severely resorbed mandibles speculated that the insertion and the loading of those different implants may have induced a physiologic "positive" microstrain to the bone, which, over time and in accordance with Wolff's law,²⁵ promoted bone apposition. In our case, as in the case described by Fish,²⁴ the HA-coating of the implant may have played a significant role in bone apposition; presumably, bone apposition could have happened over time without the additional use of rhBMP-2 and mineralized allograft, but it is very likely that these actively promoted bone formation.²⁶⁻³⁰ RhBMP-2 (Infuse bone graft) were used "off-label" in the attempt to achieve extensive bone formation

without resorting to the “osteoinductive” autogenous bone. The rationale for combining them with a mineralized allograft was to integrate an osteoinductive material (BMPs) with an osteoconductive material (allograft) in order to possibly enhance bone regeneration. A human, randomized, controlled clinical and histomorphometric study showed that combining BMP-2 with an osteoconductive bone substitute material (xenograft) in the test group enhanced the maturation process of bone regeneration and increased the graft-to-bone contact, compared with controls, where the same material was used alone.³¹ In a rabbit calvarium model on vertical guided bone regeneration, the use of rhBMP-2/ACS combined with osteoconductive bone substitute materials resulted in a greater amount of bone formation than the one produced with the osteoconductive bone substitute materials alone or rhBMP-2/ACS and blood clot.³² Furthermore, in a case report where a maxillary sinus was grafted with the same graft materials used in our case (Infuse bone graft and Puros allograft), the bone core biopsy showed new bone formation in direct contact with the allogenic bone, which appeared to have acted as scaffold.³³ A combination of Infuse bone graft and Puros allograft was used also to attain successful bone regeneration in an alveolar cleft palate patient.³⁴ In our case report no jig was used to standardize the i-CAT images. However, we tried to be as accurate as possible. We used as landmark references the area immediately distal to the radiographic image of the digastric fossae (for the pre-op and post-op i-CAT images) and the canine abutments of the subperiosteal implant (for the post-op i-CAT follow-up). The cross-sectional images were closely approximated to the area corresponding to the canine position. The authors are fully aware of the fact that the images presented in this article are not entirely superimposable; therefore, they decided not to include any linear measurements in this report. However, in spite of the fact that some margins of error may exist, the preoperative, immediate postoperative and 32-month postoperative images clearly show visual evidence of the amount of bone regeneration achieved as well as the preoperative bone level status. Postoperative bone formation appears to be the result of a regenerative process, rather than just an adaptation of the bone under the stimulus of the implant load. In all probability, the subperiosteal

implant frame acted as a rigid barrier, which allowed bone regeneration. Therefore, the subperiosteal implant shape may also play an important role in these types of cases.

In our case report, the postoperative follow-up was uneventful and the patient did not experience any adverse events. The most frequently reported adverse events with autogenous bone or BMPs grafting procedures are mainly pain, oral edema, face edema, and oral erythema. In certain cases, edema may have an important clinical relevance. Evaluation of studies comparing face edema as an adverse event after grafting procedures with autogenous bone or BMPs for oral and maxillofacial applications showed a higher incidence, although not statistically significant, of face edema when BMPs were used.³⁵ It is worth noting that the collective data from the same studies mentioned above, showed that the BMPs group had fewer adverse events than the autogenous bone graft group.³⁵ BMPs induce recruitment of inflammatory cells and fluids and may potentially cause severe soft tissue swelling. This edema, as shown in a rat model, is dependent on the dosage.³⁶ To the authors' knowledge, in dental literature there are no documented cases of dangerous swelling after use of BMPs. However, recent orthopedic and pediatric surgery literature reports adverse soft tissue swelling, which is often associated with an “off-label” use of BMPs, leading to serious complications.³⁷⁻⁴² It is believed that edema is the reason why BMPs are approved only for lumbar spine surgery and not for cervical spine surgery. As in our case, whenever large amounts of BMPs are used “off-label” in the mandible, a potential edema of the floor of the mouth, which may occur few days after the surgery, has to be taken into consideration before planning such a procedure, in order to prepare for potential complications.

CONCLUSION

Grafting the atrophic mandible with mineralized allograft and rh-BMP-2 at the time of subperiosteal implant insertion may lead to substantial bone formation.

Additional studies are needed to evaluate the extent to which rhBMP-2/mineralized allograft may be useful when used in conjunction with subperiosteal implants, and whether this technique can

predictably induce new bone formation and influence the long-term success in those selected cases in which subperiosteal implants may be indicated.

Bone morphogenetic proteins (BMPs) show great potential in terms of regenerative therapy. However, some concerns still remain, especially regarding the long-term side effects.⁴³ Human studies using rhBMP-2 have not demonstrated systemic toxicity.⁴⁴⁻⁴⁸ However, there are no adequate and well-controlled studies on pregnant women. There are rising concerns regarding the interference of possible maternal anti-BMP antibodies⁴⁹ on BMP-dependent processes in a developing embryo⁵⁰⁻⁵⁴ as well the effects of BMPs on a developing skeleton.⁵⁵ Both BMPs and BMP receptors have been isolated from human tumors.^{56,57} BMP-2 has stimulatory and inhibitory effects on different pancreatic tumor cell lines.⁵⁸ Despite the evidence that some BMPs and their receptors can be found in tumors, there is no evidence that they are actually carcinogenic. Their presence does not mean that they induced neoplasia. They are most likely upregulated.⁵⁹ Existing data is encouraging, and although long-term follow-up is not yet available, intermediate data reveals a benign side profile.⁴³

BMPs represent a valuable treatment option for regenerative therapy. As previously stated, in the case presented in this article the patient did not experience any complications. However, further studies are needed to evaluate the "off-label" use of BMPs.

NOTE

The US Food and Drug Administration approves rhBMP-2 (Infuse bone graft) as "an alternative to autogenous bone graft for sinus augmentation and for alveolar ridge augmentation for defects associated with extraction sockets." Furthermore, the clinical trials used for rhBMP-2 (Infuse bone graft) evaluation used only rhBMP-2 by itself, without any addition of allograft or xenograft. In our clinical report, rhBMP-2 (Infuse bone graft) was used "off-label." The patient signed a written consent form for off-label use prior to the surgical procedure. The authors declare no conflict of interest of any sort. Also, this case was not financially or otherwise supported by any company nor any other venture capitalist.

ABBREVIATIONS

ACS: absorbable collagen sponge
 BMP: bone morphogenetic protein
 CBCT: cone-beam computerized tomography
 HA: hydroxyapatite
 rhBMP-2: recombinant bone morphogenetic protein-2

REFERENCES

1. Linkow Li. Evolutionary design trends in the mandibular subperiosteal implant. *J Oral Implantol.* 1984;11:402-438.
2. Boyne P, James RA. Advances in subperiosteal implant reconstruction. *Dental Clin North Am.* 1986;30:259-268.
3. James RA, Lozada JL, Truitt PH, Foust BE, Jovanovich SA. Subperiosteal implants. *CDA J.* 1988;16:10-14.
4. Dahl GSA. Regarding the possibility of implanting metal skeletons in the jaws as a base or retention of fixed or removable prostheses [In Swedish]. *Odont Tidskrift.* 1943;52:440-446.
5. Goldberg NI, Gershkoff A. The implant lower denture. *Dent Dig.* 1949;55:490-494.
6. Bloomquist DS. Long-term results of subperiosteal implants combined with cancellous bone graft. *J Oral Maxillofacial Surg.* 1982;40:348-352.
7. Kratochvil FJ, Boyne P. Combined use of subperiosteal implant and bone-marrow graft in deficient edentulous mandible: a preliminary report. *J Prosthet Dent.* 1972;27:645-653.
8. Kratochvil FJ, Boyne P, Bump RL. Rehabilitation of grossly deficient mandibles with combined subperiosteal implants and bone graft. *J Prosthet Dent.* 1976;35:452-461.
9. Golec TS, Cutri AA. Treatment of the acutely atrophic mandible with a combined subperiosteal implant and bone graft. *J Oral Implantol.* 1982;10:371-378.
10. Lee MB: Bone morphogenetic proteins: background and implications for oral reconstruction. A review. *J Clin Periodontol.* 1997;24:355-365.
11. Wozney JM. Overview of bone morphogenetic proteins. *Spine.* 2002;27:2-8.
12. Wozney JM, Rosen V. Bone morphogenetic protein gene family in bone formation and repair. *Clin Orthop Res.* 1998;346:26-27.
13. De Biase P, Capanna R. Clinical application of BMPs. *Injury.* 2005;3:43-46.
14. Truitt HP. Noninvasive technique for mandibular subperiosteal implant: a preliminary report. *J Prosthet Dent.* 1986;55:494-500.
15. James RA. Subperiosteal implant design based on peri-implant tissue behaviour. *J Dent.* 1983;53:407-414.
16. James RA. Advanced in subperiosteal implant reconstruction. *Dent Clin North Am.* 1986;30:259-268.
17. Minichetti C. Analysis of HA-coated subperiosteal implants. *J Oral Implantol.* 2003;29:111-116.
18. Bosker H, Powers MP. The transmandibular reconstruction system. In: Fonseca R, Davis WH, eds. *Reconstructive Preprosthetic Oral and Maxillofacial Surgery.* Philadelphia, PA: WB Saunders Company; 1986:565-568.
19. Powers MP, Bosker H, van Pelt H, Dunbar N. The transmandibular implant: from progressive bone loss to controlled bone growth. *J Oral Maxillofac Surg.* 1994;52:904-910.
20. Betts NJ, Barber HD, Powers MP, Wu L, Henning T, Fonseca RJ. Osseous changes following placement of the transmandibular implant system in edentulous mandibles. *Implant Dent.* 1993;2:11-17.
21. Stellingsma C, Vissink A, Meijer HJA, Kuiper C, Raghoobar

- GM. Implantology and the severely resorbed edentulous mandible. *Crit Rev Oral Biol Med*. 2004;15:240–248.
22. Batenburg RH, Stellingsma K, Rahoebar GM, Vissink A. Bone height measurements on panoramic radiographs: the effect of shape and position of edentulous mandibles. *Oral Surg Oral Med Oral Pathol Oral Radio Endod*. 1997;84:430–435.
23. Roberts RA. A 24-years retrospective study of bone growth after implant placement. *J Oral Implantol* 2005;31:98–103.
24. Fish JM, Misch CE. Mandibular bone growth induced by a hydroxylapatite-coated subperiosteal implant: a case report. *J Oral Implantol*. 2000;26:267–275.
25. Wolff J. *The Law of Bone Remodeling*. New York: Springer; 1986.
26. Minichetti C, D'Amore JC, Hong AY, et al. Human histologic analysis of mineralized bone allograft (Puros) placement before implant surgery. *J Oral Implantol*. 2004;30:74–82.
27. Noubissi SS, Lozada JL, Boyne PJ, et al. Clinical, histologic, and histomorphometric evaluation of mineralized solvent-dehydrated bone allograft (Puros) in human maxillary sinus grafts. *J Oral Implantol*. 2005;31:171–179.
28. Keith JD, Salama MA. Ridge preservation and augmentation using regenerative materials to enhance implant predictability and aesthetics. *Compendium*. 2007;28:614–623.
29. Misch CM. Bone augmentation of the atrophic posterior mandible for dental implants using rhBMP-2 and titanium mesh: clinical technique and early results. *Int J Periodontics Restorative Dent*. 2011;31:581–589.
30. Ciccù M, Herford AS, Stoffella E, Cervino G, Ciccù D. Protein-sigaled guided bone regeneration using titanium mesh and rh-bmp2 in oral surgery: a case report involving left mandibular reconstruction after tumor resection. *Open Dent J*. 2012;6:51–55.
31. Jung RE, Glauser R, Hämmerle CH, Sailer HF, Weber FE. Effect of rh-BMP-2 on guided bone regeneration in humans. *Clin Oral Implants Res*. 2003;14:556–568.
32. Polo CL, Oliviera Lima JL, De Lucca L, et al. Effect of recombinant human bone morphogenetic protein 2 associated with a variety of bone substitute on vertical bone regeneration in rabbit calvarium. *J Periodontol*. 2013;84:360–370.
33. Whitesides LM, Radwan A, Sharawy M. Sinus floor augmentation using a composite graft of bone morphogenetic protein-2 and allogenic cancellous bone (Puros): case report. *J Oral Implantol*. 2006;32:259–264.
34. Le BT, Woo I. Alveolar cleft repair in adults using guided bone regeneration with mineralized allograft for dental implant site development. A report of 2 cases. *J Oral Maxillofac Surg*. 2009;67:1716–1722.
35. Food and Drug Administration 2007. Summary of safety and effectiveness data. http://www.accessdata.fda.gov/cdrh_docs/pdf5/P050053b.pdf. Accessed September 1, 2014.
36. Lee KB, Taghavi CE, Murray S, Song KI, Keorochana G, Wang JC. BMP induced inflammation: a comparison of rh-BMP-7 and rhBMP-2. *J Orthop Res*. 2012;30:1985–1994.
37. Shields LBE, Raque GH, Glassman SD, et al. Adverse effects associated with high-dose recombinant human bone morphogenetic protein-2 use in anterior cervical spine fusion. *Spine*. 2006;31:542–547.
38. Smucker JD, Rhee JM, Singh K, et al. Increased swelling complications associated with off-label usage of rhBMP-2 in the anterior cervical spine. *Spine*. 2006;31:2813–2819.
39. Perri B, Cooper M, Laurysen C, Anand N. Adverse swelling associated with use of rh-BMP-2 in anterior cervical discectomy and fusion: a case study. *Spine J*. 2007;7:235–239.
40. Shah MM, Smyth MD, Woo AS. Adverse facial edema associated with off-label use of recombinant human bone morphogenetic proteins-2 for cranial reconstruction for craniosynostosis. *J Neurosurg Pediatr*. 2008;1:255–257.
41. Tumalian LM, Rodts GE. Adverse swelling associated with use of rh-BMP-2 in anterior cervical discectomy and fusion. *Spine J*. 2007;7:509–510.
42. Carragee EJ, Hurwitz EL, Weiner BK. A critical review of recombinant human bone morphogenetic protein-2 trials in spinal surgery: emerging safety concerns and lessons learned. *Spine J*. 2011;11:471–491.
43. Smith DM, Cooper GM, Mooney MP, Marra KG, Losee JE. Bone morphogenetic protein 2 therapy for craniofacial surgery. *J Craniofac Surg*. 2008;19:1244–1259.
44. Boden SD, Martin GJ, Wall N, et al. Bone. Posterolateral lumbar intertransverse process spine arthrodesis with recombinant human bone morphogenetic protein-2/hydroxyapatite-tricalcium phosphate after laminectomy in the non human: a preliminary report. *Spine*. 1999;24:1179–1186.
45. Boyne PJ, Marx RE, Nevis M, et al. A feasibility study evaluating rhBMP-2/absorbable collagen sponge for maxillary sinus floor augmentation. *Int J Periodontics Restorative Dent* 1997;17:1–25.
46. Cochran SD, Baffets GC, Wolfe MW, Sanpath TK, Rueger DC, Whitecloud TS 3rd. The effect of recombinant human osteogenic protein-1 on healing large segmental bone defects. *J Bone Joint Surg Am*. 1994;76:872–838.
47. Kleeman TJ, Ahn UM, Talbot-Kleemans A. Laparoscopic anterior lumbar interbody fusion with rh-BMP-2: a prospective study of clinical an radiographic outcomes. *Spine*. 2001;26:2751–2756.
48. McKay W, Medtronic Sofamore Danek. Personal communication. Study on file with FDA, Rockville, MD, 2001.
49. Lindholm TC, Lindholm TS, Martittinen, et al. Bovine bone morphogenetic protein (bBMP/NCP)-induced repair of skull trephine defects in pigs. *Clin. Orthop Relat Res*. 1994:263–270.
50. Chen D, Zhao M, Mundy GR. Bone morphogenetic proteins. *Growth Factors*. 2004;22:233–241.
51. Machingo QJ, Fritz A, Shur BD. A beta 1,4-galactosyltransferase is required for BMP2-dependent patterning of the dorso-ventral axis during zebrafish embryogenesis. *Development*. 2006;133:2223–2241.
52. Ebendal T, Bengtsson H, Soderstrom S. Bone morphogenetic proteins and their receptors: potential functions in the brain. *J Neurosci Res*. 1998;51:139–146.
53. Kanzler B, Foreman RK, Labosky PA, Mallo M. BMP signaling is essential for development of skeletogenic and neurogenic cranial neural crest. *Development*. 2000;127:1095–1104.
54. Piscitone TD, Yager TD, Gupta IR, et al. BMP and OP-1 exert direct and opposite effects on renal branching morphogenesis. *Am J Physiol*. 1997;273:F961–F975.
55. Springer IN, Acil Y, Kuchenbecker S, et al. Bone graft versus BMP-7 in a critical sized defect-cranioplasty in growing infant model. *Bone*. 2005;37:563–569.
56. Laitinen M, Jortikka L, Haltunnen T, et al. Measurement of total and local bone morphogenetic protein concentration in bone tumors. *Int Orthop*. 1997;21:188–193.
57. Yoshikawa H, Retting WJ, Lane JM. Immunohistochemical detection of bone morphogenetic protein in bone and soft tissue sarcomas. *Cancer*. 1994;74:842–847.
58. Kleeff J, Maruvama H, Ishiwata T. Bone morphogenetic protein-2 exerts diverse effects on cell growth in vitro and is expressed in human pancreatic cancer. *Gastroenterol*. 1999;116:1202–1216.
59. Poynton AR, Lane JM. Safety profile for clinical use of bone morphogenetic protein in the spine. *Spine*. 2002;27:40–48.