

# ANALYSIS OF HA-COATED SUBPERIOSTEAL IMPLANTS

John C. Minichetti, DMD

## KEY WORDS

Hydroxyapatite  
Subperiosteal implant  
CT scanning  
Bone impression

Bone atrophy is often encountered in the edentulous patient. With many clinicians performing bone grafting and augmentation techniques, there appears to be a decreased use of the subperiosteal implant modality for prosthetic stabilization. In recent years, there seems to be a decreasing number of literature reports and fewer academic presentations about the subperiosteal implant technique. Additionally, the American Academy of Implant Dentistry deleted this requirement for fellowship in its bylaws at its 1999 annual meeting. The purpose of this paper is to present the success and complication rates of 22 hydroxyapatite-coated subperiosteal implants placed over a 10-year period. Correlations between arch type and full vs unilateral subperiosteal implant cases are analyzed.

## INTRODUCTION

Implant dentistry has seen tremendous growth and advances over the past decade. With the advent, development, and better understanding of bone augmentation techniques, root form implantology is now overwhelmingly the modality of choice. The subperiosteal implant technique is not recommended as frequently as it once was.

The subperiosteal implant was designed to rest on top of the bone and beneath the periosteum. Its design was created to distribute stress from the prosthesis to large areas of supporting bone. Retention is obtained by the mucoperiosteum; when it becomes reattached, it stabilizes the infrastructure casting.

Gustav Dahl proposed the original implant design and insertion protocol in 1937.<sup>1(p431)</sup> Many clinicians modified the technique and design of this im-

plant, primarily in the United States, after its introduction by Gershoff and Godberg in 1948.<sup>1(p432)</sup> The full subperiosteal implant is fabricated to offer complete arch support for an overdenture usually used for the fully edentulous arch. The prosthesis most frequently used with a full subperiosteal is the RP-4 (a removable implant-supported prosthesis).<sup>1(p429)</sup> The unilateral subperiosteal implant is usually employed as the distal abutment for a fixed prosthesis such as an FP-2 or FP-3. An FP-2 is a fixed prosthesis with tooth and root structure, and an FP-3 is a fixed prosthesis with tooth, root, and soft tissue structure.<sup>2</sup>

## HA coating

Subperiosteal implants have been fabricated from chrome cobalt alloy since 1940.<sup>1(p433)</sup> Coating of the subperiosteal

*John C. Minichetti, DMD, is an attending dentist at the Englewood Hospital, Englewood, NJ, as well as in private practice. Address correspondence to Dr Minichetti at 370 Grand Avenue, Englewood, NJ 07631 (e-mail: dminichett@aol.com).*

implant with hydroxyapatite (HA) was introduced by Rivera in the 1980s to improve the likelihood of direct bone contact to the implant.<sup>3</sup> The use of HA coating provided a stimulus for the reinterest in the placement of the subperiosteal implant in the late 1980s and early 1990s. Several authors reported data on the use of HA-coated implants during that time period.<sup>4-7</sup> The use of HA coating with implants is recommended because it has been observed and reported to improve the chance of direct bone-to-implant interface, to decrease strut dehiscence, and to improve the soft tissue environment.<sup>8</sup>

### *Subperiosteal fabrication*

There are two main techniques for fabricating the subperiosteal implant. A direct bone impression technique is the original method employed. It involves a 2-stage surgical maneuver. On the first surgical visit, a bone impression and bite registration is taken, usually with a polyvinyl siloxane material. A bone model is made in dental stone and mounted at the proper vertical dimension for the subperiosteal implant fabrication. After the implant is cast, a second surgical visit is required for its insertion. The first and second surgical visits are usually separated by a 6-week period to allow for periosteal reattachment.<sup>1(p441)</sup>

In 1985, Truitt developed a computerized tomography (CT) scanning technique.<sup>9</sup> This method enabled the clinician to obtain a bone model using CT and a computer-generated model (CAD/CAM), or sterolithography, thereby eliminating the first-stage surgery. The CT scan is performed on the patient prior to any surgical visit. The bone model is mounted using a bite registration or the buccal tube and stylus technique as described by Cranin.<sup>10</sup> One surgical visit is needed to insert subperiosteal implants fabricated with this technique.

### LITERATURE REPORTS

In the late 1980s and early 1990s, several authors reported favorable statis-

tics with HA-coated subperiosteal implants using both the direct bone impression technique and CT-generated subperiosteal implants. In 1991, Kay, Golec, and Riley<sup>4</sup> reported 4 years of clinical experience with HA-coated subperiosteal implants. Their findings showed an overall success rate of 98.2% in over 300 cases using the bone impression technique and CT scan-fabricated subperiosteal implants. The same year, Misch and Dietsh published their results on 24 unilateral HA-coated subperiosteal implants. Their findings reported an impressive success rate of 100% over a 10-year period.<sup>5</sup> In 1992, Benjamin presented a 6-year retrospective study on over 700 CT-scan, HA-coated subperiosteal implants, reporting a success rate of 98%. He showed a <10% complication rate in his report.<sup>7</sup>

A more recent publication in 1997 by O'Roark reported success rates of 85-100% on 362 subperiosteal implants over a 6-10-year period.<sup>11</sup> The consensus report of the American Academy of Implant Dentistry (AAID) presented by clinicians Weiss, Linkow, Clark, and Nathan concluded that both maxillary and mandible, full and unilateral, HA-coated subperiosteal implants were viable and recommended techniques for both fixed and removable prostheses.<sup>12</sup>

### METHODS

#### *Mandibular unilateral subperiosteal implants*

Less than 10 mm of vertical bone height often precludes the use of endosseous root form implants without vertical augmentation (Division C bone). Division C bone is an edentulous area, which exhibits either <2.5 mm in width, <10 mm in height, a crown-implant ratio  $\geq 1$ , and/or an angulation >30 degrees, regardless of the position of the implant body into the edentulous site.<sup>13</sup> Therefore, the primary indication for a unilateral subperiosteal implant is a partially edentulous Kennedy Class II patient, missing all posterior teeth on one side, with

Division C bone.<sup>1(p444)</sup> A Kennedy Class II patient has a unilateral edentulous area located posterior to the remaining natural teeth.<sup>14</sup> Bone atrophy and resorption of the ridge often follow the lack of posterior teeth in the mandibular arch, particularly if a removable partial denture has been worn over extended periods.

The unilateral subperiosteal implant can be fabricated from a bone impression or with a CT-generated model. For the bone impression, an incision is made over the crest of the ridge with a vertically ascending ramus-releasing incision. It is also recommended that an anterior releasing incision be used to allow for adequate ridge exposure.<sup>1(p445)</sup> A full-thickness periosteal flap is made in order to expose the underlying residual ridge and lateral aspects of the mandible. After the impression is made, a bone bite registration is necessary for mounting the bone model and achieving accurate location for the planned fixed prosthesis abutments. Primary closure with 3-0 silk or chromic gut sutures is common.

The direct bone impression is boxed and poured with die stone, and the framework is designed. The gingival collar areas and the abutments are the only polished surfaces. The implant is cast in chrome-cobalt-molybdenum alloy and coated with HA. Implant placement is performed at least 6 weeks after the bone impression to allow for the healing of the periosteum.<sup>16</sup> The surgical incision is the same as in stage I surgery. Adequate reflection is necessary in order to confirm the proper seating of the periosteal. Stability of the implant is observed, and the connection of the infrastructure to the underlying bone is confirmed. Any minor discrepancies between the implant and underlying bone are filled with particulate HA.<sup>1(p441)</sup> A tension-free primary closure is made, and a provisional acrylic temporary prosthesis is constructed with light occlusal contacts. The patient is given postoperative instructions, appropriate antibiotics, and analgesics. Sutures are removed 1 to 2

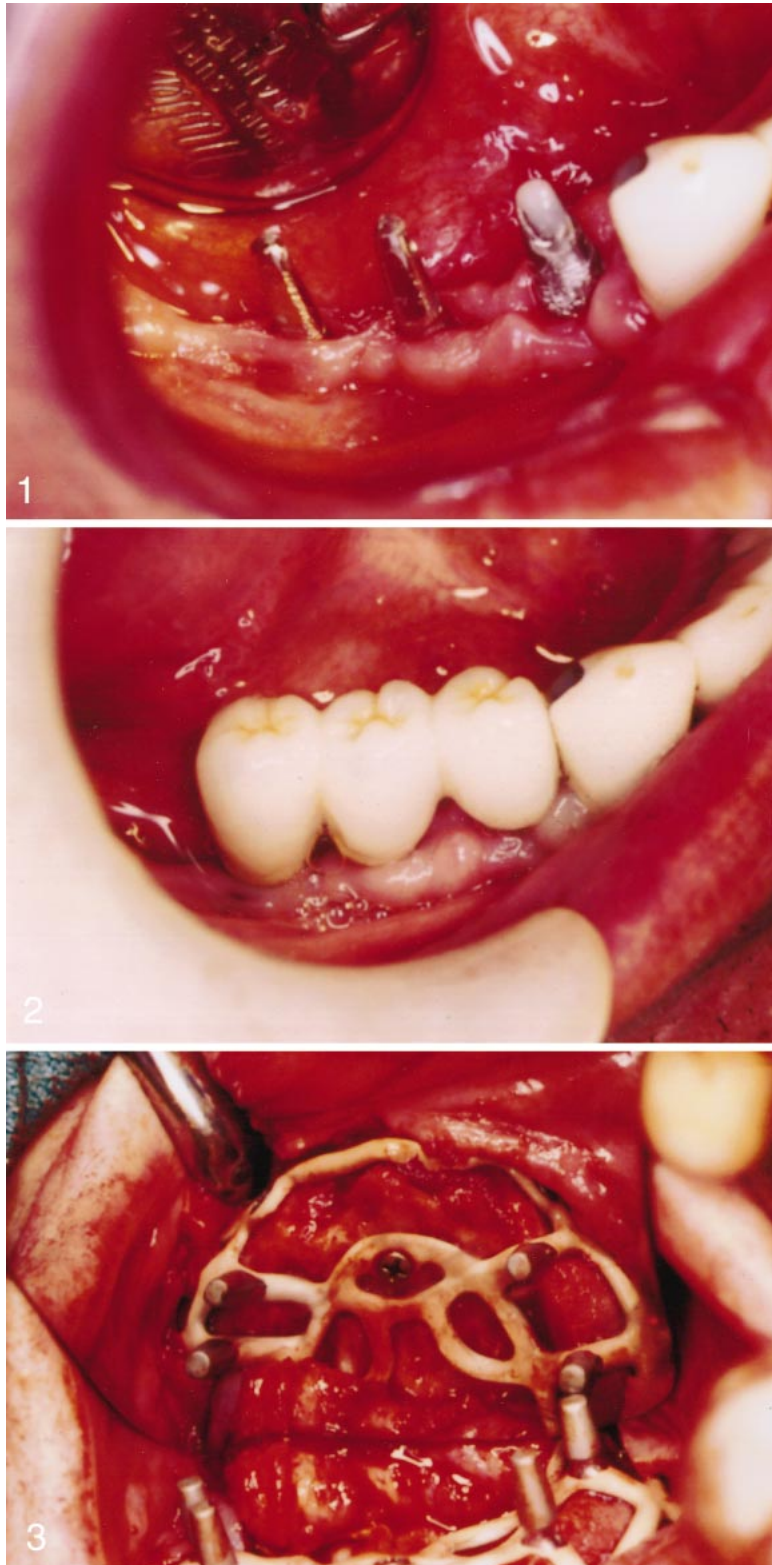

FIGURE 1. Two distal abutments of the subperiosteal implant will be splinted to the anterior implant abutment. Abutment posts are tapered for conventional cementable fixed porcelain fused to metal prosthesis fabrication.

FIGURE 2. Inserting a 3-unit fixed bridge creates an implant-independent prosthesis.

FIGURE 3. Full palatal reflection allows for placement of a subperiosteal implant from a computerized tomography scan and computer-generated model. Note the intimacy of fit

weeks postoperatively, and final prosthetic construction is begun 6 to 8 weeks later. Postoperative complications are few, and can include temporary tooth sensitivity, incision line dehiscence, swelling, pain, and buccinator muscle pull.

The final prosthesis in this series was an FP-2 (fixed prosthesis with tooth and root structure) porcelain fused-to-high noble metal restoration connecting 2 abutments of the subperiosteal implant to the anterior teeth (Figure 1). Small buccal/lingual occlusal tables of premolar width were used to minimize lateral forces on the implant. Adequate embrasure spaces for sufficient oral hygiene were emphasized (Figure 2).

#### *Full maxillary subperiosteal implant*

The maxillary full subperiosteal implants in this study were fabricated with a direct bone impression or the CT scan technique. The surgical procedure for the bone impression technique was similar to that described for the unilateral implant. In several atrophic maxillae, the CT scan technique was invaluable because dehiscent sinuses were often encountered. The implants were designed with the infrastructure supported by the zygomatic arch, nasal spine, and midpalatine suture, thereby circumventing the maxillary sinuses and nasal floors (Figure 3).

#### STUDY CASES

Records of 22 subperiosteal implants placed over an 11-year period were reviewed. Patients were categorized into age, sex, date of placement, complications, full or unilateral subperiosteal implant, CT scan-generated construction, arch type, current status, opposing dentition, months in function, and whether splinted to natural teeth (Table 1). Time of implant in situ

←

of the subperiosteal implant. Defects in the bone are augmented with guided tissue regeneration (GTR) membranes and allogenic bone grafts.

TABLE  
Statistical data—10 years\*

Patient	Age	Sex	Date Placed	Comp	Type	Jaw	Present	Opposing Jaw	Months	Splinted
1	76	F	7/25/90	Y/Sect/B	F	Max	Firm	Root Forms	144	N
2	64	F	7/22/92	N	F	Max	Firm	Root Forms	120	N
3	54	F	4/21/93	Y/Hyp	F	Mand	Firm	Subperiosteal	104	N
4	54	F	4/21/93	N	F	Max	Firm	Subperiosteal	104	N
5	66	M	4/26/93	Y/Sect/B	U	Mand	Failed	Natural	87	Y
6	51	F	7/28/93	N	U/CT	Mand	Firm	Natural	108	Y
7	51	F	7/28/93	N	U/CT	Mand	Firm	Natural	108	Y
8	68	M	10/22/93	Y/Sect/B	U	Max	Firm	Natural	105	Y
9	55	F	10/28/94	N	U	Max	Firm	Root Forms	93	N
10	55	F	10/28/94	N	U	Max	Firm	Root Forms	93	N
11	77	F	3/14/95	N	F	Max	Firm	Root Forms	88	N
12	87	M	3/22/95	N	U	Max	Firm	Root Forms	88	Y
13	77	F	3/28/95	Y/Curr	F/CT	Max	Firm	Blades	88	N
14	65	M	6/22/95	N	U	Max	Firm	Root Forms	85	Y
15	66	F	4/13/96	Y/Sect/B	U	Mand	Failed	Natural	47	Y
16	60	M	8/1/96	Y/Curr	U	Mand	Firm	Natural	71	N
17	80	M	8/8/96	Y/Curr	U	Max	Firm	Natural	71	Y
18	57	F	10/21/96	N	U	Mand	Firm	Natural	69	Y
19	56	M	11/29/96	N	F/CT	Max	Firm	Overdenture	68	N
20	40	F	6/20/97	N	U	Mand	Firm	Natural	51	Y
21	40	F	6/20/97	N	U	Mand	Firm	Natural	51	Y
22	39	M	11/21/97	N	U	Mand	Firm	Natural	46	Y

\*B indicates bone grafting; Comp, complication; CT, fabricated with the use of a computer-generated model; Curr, curettage and irrigation; F, full subperiosteal implant; Hyp, removal of hyperplastic tissue; Mand, mandibular; Max, maxillary; N, no; Sect, sectioning of strut; U, unilateral subperiosteal implant; Y, yes.

ranged from 46 to 144 months (4 to 12 years) with a mean range of 86 months (7 years). The ages of patients treated ranged from 39 to 81 years. The mean average age of patients treated was 60.8 years. Seven of the implants were of the full arch design and 15 were unilateral. Twelve had been placed in the maxilla and 10 in the mandible. Four of the implants had been constructed with the CT scan technique, and 18 had been cast from a bone model impression. All 22 subperiosteal implants were restored with either a Misch/Judy classification FP-2 (fixed prosthesis replacing tooth and root structure) or FP-3 (fixed prosthesis with tooth, root, and soft tissue) fixed-implant prosthesis.<sup>2</sup>

## RESULTS

A successful implant was classified as any subperiosteal implant remaining in occlusal function over the study period. A failure was any implant that had to be totally removed because of pain, swelling, infection, or significant bone loss. A subperiosteal implant was classified with a complication when-

ever treatment or intervention was necessary, such as curettage and irrigation of abutment posts or struts, surgical pocket elimination, bone grafting, or revisional sectioning of any portion of the subperiosteal struts.

Of the 22 subperiosteal implants, 2 required complete removal, for an overall success rate of 91% (Figure 4). Analysis of the 12 maxillary subperiosteal implants indicated a 100% success rate. The longest implant in function was in place for 12 years. In the mandibular arch, there was an 80% success rate, with 2 mandibular unilateral subperiosteal implants removed (Figure 5). Comparison of full subperiosteal implants to unilateral subperiosteal implants showed a 100% success rate for full subperiosteal implants and an 87% success rate for unilateral implants.

Complication rates for the subperiosteal implants were higher than success rates. An overall complication rate of 36% was noted. This complication rate includes the 2 failed implants and 6 implants that required some type of treatment, with or without surgery.

Four subperiosteal implants required curettage and irrigation around the abutment posts. One full subperiosteal implant required surgical removal of hyperplastic tissue. Four implants required flap surgery and bone augmentation of osseous defects that developed beneath the permucosal abutment areas. Four implants (2 of which failed) required sectioning of one or more of the peripheral struts because of significant bone resorption in combination with bone grafting. When grafting was performed, it consisted of HA and demineralized freeze-dried bone allograft (DFDB) mixtures with or without strut removal.

The complication rates of full subperiosteal implants compared with unilateral implants were 29% to 41%. A 100% success rate was found for the 4 CT-generated implants (Figure 6). There was a 33% complication rate in the maxillary arch (of 12 implants, 4 needed treatment) and a 40% complication rate in the mandibular arch (of 10 implants, 4 needed treatment).

DISCUSSION

All of the patients in this study had significant bone atrophy that would have required bone grafting procedures prior to placement of root form implants. Therefore, subperiosteal implants were chosen. The subperiosteal implant offers the advantage of eliminating bone augmentation prior to implant placement. This can reduce treatment time significantly; when CT scanning is used, the implant can be placed and restored within a few weeks. This is particularly beneficial for elderly patients. The subperiosteal implant is often more cost effective than traditional root form implants.

Disadvantages of the subperiosteal technique include larger surgical flap elevation and management. Postoperative swelling and edema are common. The placement technique is more demanding than that of conventional root form implant placement.

Failure rates in this report are similar to those reported by others.<sup>4-7</sup> The overall complication rate of 36% reported in this analysis is higher than those reported by others. This could be a result of the definition of complication in this report, which ranges from minor curettage to surgical intervention. The complication rate for HA-coated subperiosteal implants in this study might be one of the factors that influences clinicians in their choice of implant modalities.

CONCLUSION

The purpose of this paper was to present the results of 22 subperiosteal implants placed over a 10-year period. An overall success rate of 91% was similar to those found in previous reports,<sup>4-7</sup> but a complication rate of 36% was higher. In general, there appears to be less interest in the literature and continuing education courses with regard to subperiosteal implants. An explanation could be that potential complications for this technique are high, and clinicians might be challenged when treating these problems. Proliferation

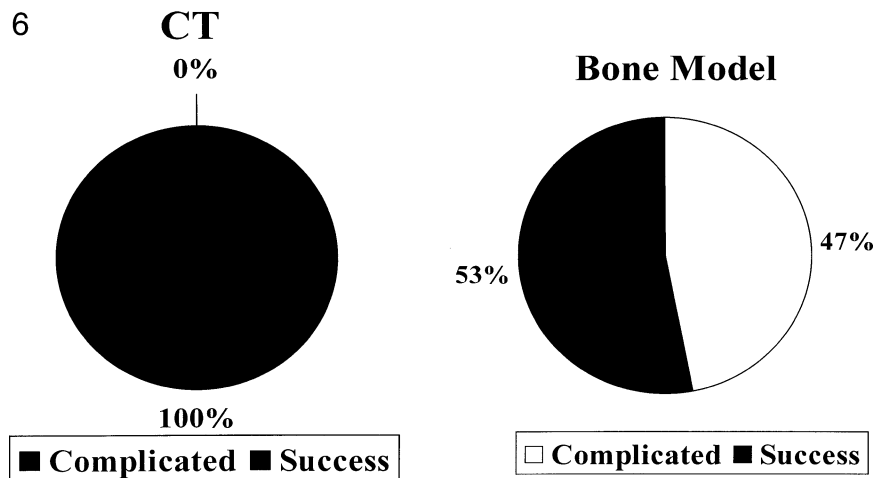
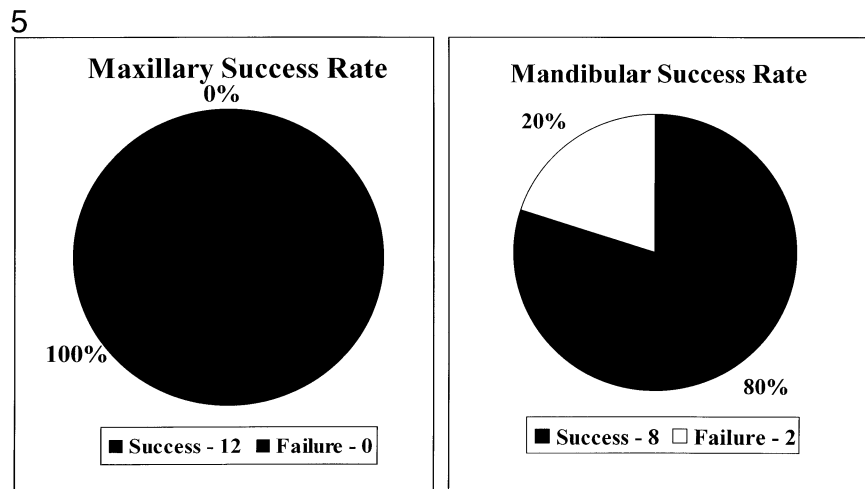
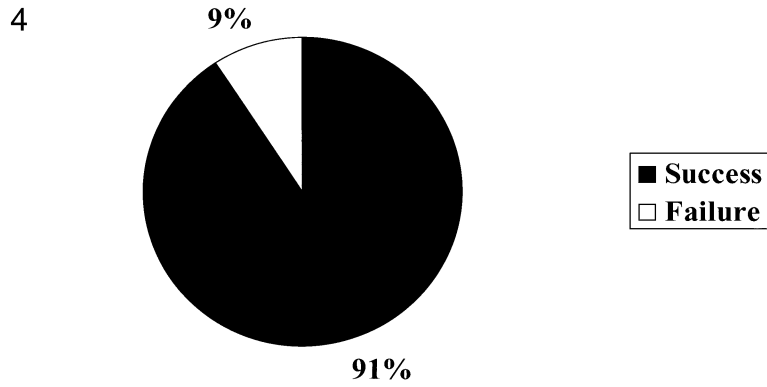


FIGURE 4. Chart demonstrating an overall success rate of 91% for a total of 22 subperiosteal implants.

FIGURE 5. Chart comparing the overall success rate of maxillary vs mandibular arch subperiosteal implants.

FIGURE 6. Chart comparing the success rates of the computerized tomography scanning vs bone impression technique for fabrication of the subperiosteal implant.

of bone regenerative technology in the past decade facilitating the use of root form endosseous implants might be another explanation.

ACKNOWLEDGMENTS

The author acknowledges Creative Custom Service laboratory and A & C

laboratory for their assistance with these cases, as well as Lauren Minichetti for her assistance with the statistical data and graphs.

#### REFERENCES

1. Misch CE. *Contemporary Implant Dentistry*. 2nd ed. St. Louis, Mo: Mosby; 1999.
2. Misch CE. Bone classification: training keys. *Dent Today*. 1989;8:39-44.
3. Rivera E. HA castings on the subperiosteal implant. International Congress of Oral Implantology, San Juan, Puerto Rico, 1983.
4. Kay JK, Golec TS, Riley RL. Hydroxylapatite coated subperiosteal dental implants status and four year clinical experience. *J Oral Implantol*. 1991;8:11-16.
5. Misch CE, Dietsch F. The unilateral mandibular subperiosteal implant—indications and technique. *J Oral Implantol*. 1991;8:21-27.
6. Golec TS, Krauser JT. Long-term retrospective studies on hydroxyapatite coated endosteal and subperiosteal implants. *Dent Clin North Am*. 1992;36:39-65.
7. Benjamin L. Long-term retrospective studies on the CT scan CAT/CAD one stage surgery hydroxyapatite-coated subperiosteal implants, including human functional retrievals. *Dent Clin North Am*. 1992;36:77-93.
8. Han J. The unilateral subperiosteal implant. *Int J Oral Implantol*. 1991;8:136-145.
9. Truitt HP. Noninvasive technique for mandibular subperiosteal implant: a preliminary report. *J Prosthet Dent*. 1986;55:494-500.
10. Cranin N, Klein M, Sirakian A. Tech for mounting computer generated models for subperiosteal implants: the Brookdale tube and stylus centric system. *J Oral Implantol*. 1993;16:52-56.
11. O'Roark W. Survival rate of dental implants: an individual practitioner's anecdotal review of 25 years of experience. *J Oral Implantol*. 1994;20:43-47.
12. Weiss CM, Reynolds T. A collective conference on the utilization of subperiosteal implants in implant dentistry. *J Oral Implantol*. 2000;26:127-128.
13. Misch CE, Judy KWM. Classification of partially edentulous arches for implant dentistry. *Int J Oral Implantol*. 1990;7:9-17.
14. Baker JL, Goodkind RJ. *Theory and Practice of Precision Attachment of Removable Partial Dentures*. St Louis, Mo: Mosby; 1981.
15. Cranin AN. *An Atlas to Oral Implantology*. 1st ed. New York, NY: Thieme Medical Publishers; 1993.